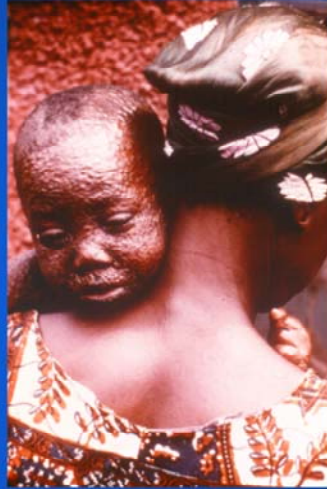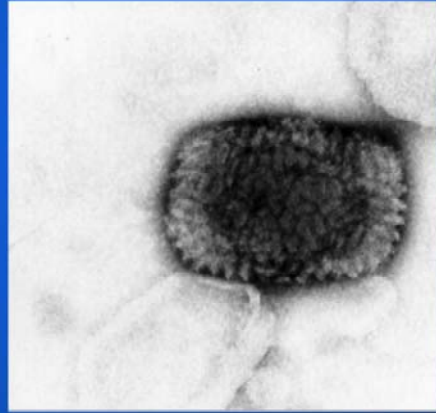


Smallpox Disease and Its Clinical Management



Smallpox: Overview

- Variola; an orthopoxvirus
- Humans only known reservoir
- Person-to-person transmission (droplet/contact)
- Up to 30% mortality in unvaccinated



Smallpox Clinical Case Definition

- Acute onset of fever 101F or higher.
- Rash development following fever.
- Rash characterized by:
 - Firm.
 - Deep-seated vesicles or pustules.
 - Same state of development.
 - Without other apparent cause.

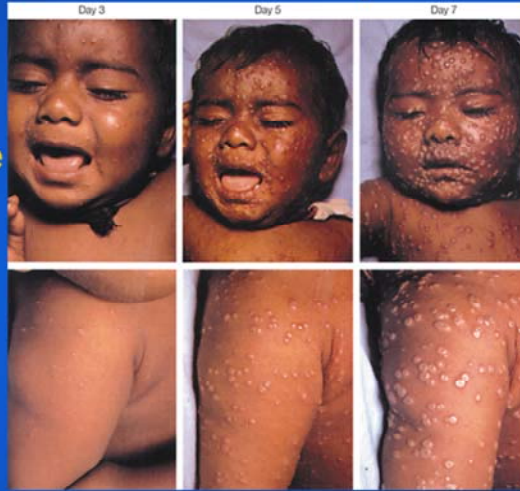

This is the clinical case definition of smallpox.

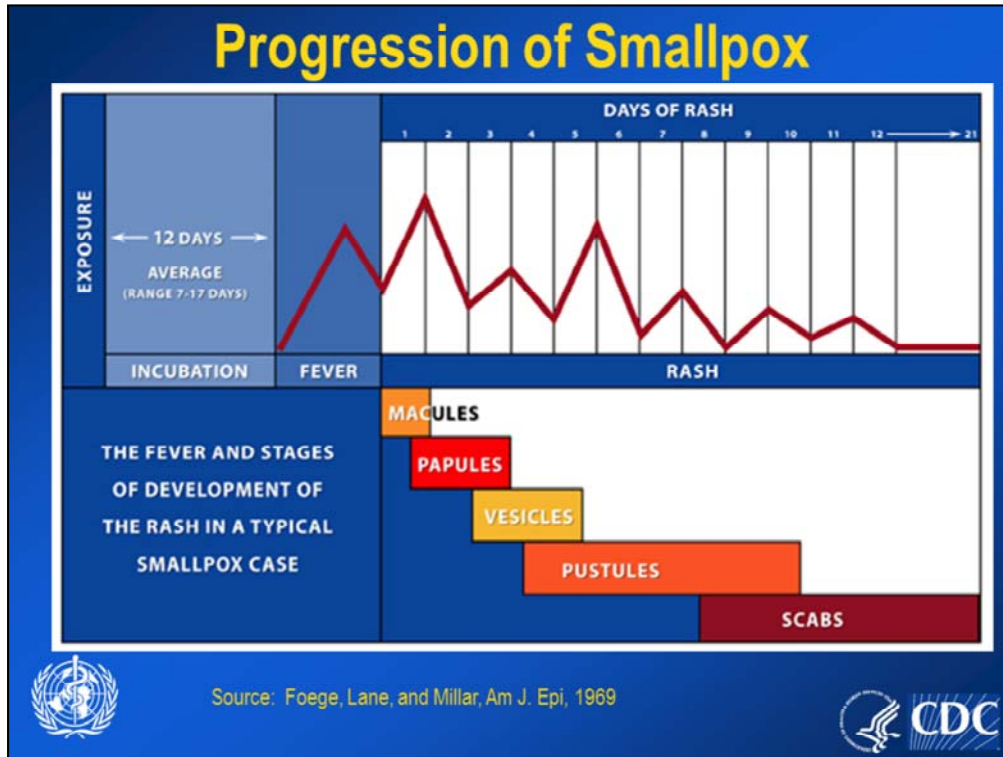
It's an illness with an acute onset of fever of 101 Fahrenheit or higher, followed by a rash. The rash is characterized by firm, deep seated vesicles or pustules in the same state of development without other apparent cause.

Typical Progression of Smallpox

- Incubation Period
- Pre-eruptive Stage
- Macules
- Papules
- Vesicles
- Pustules
- Scabs
- Scars



The rash typically progresses over a period of about 2 weeks. There are 2 pre-rash stages; the incubation period and pre-eruptive stage. We'll talk about these stages in more detail later. The actual rash stages (the period of highest infectivity) include: macular, papular, vesicular, and pustular stages. Finally the skin lesions scab over and patients are often left with permanent scarring.



Here we see a cartoon presentation of the progression of disease. The fever curve is plotted against the stages of rash. Also included is information about the period of infectivity. Infectivity is related to viral titers in the saliva (responsible for droplet transmission of disease) and the rash skin lesions (responsible for contact transmission of disease). Virus titers in saliva are highest during the first week of the skin rash, corresponding with the period during which patients are most infectious.

There are two major forms of smallpox: variola major is a severe illness with a high fatality rate; variola minor is much less frequently fatal. We will focus on variola major during this lecture.

Progression of Smallpox Incubation Period

- Average incubation period (the interval between exposure and first symptoms) is 10-14 days.
- Range is as short as 7 days and as long as 17 days.



The incubation period of smallpox averaged 12 days, with a range of 7 to 17 days. During this period the patient is well and not infectious.

Progression of Smallpox Pre-Eruptive Stage

- Sudden onset of fever (38.5-40.5C or 101.3 -104.9F) and malaise.
- Toxic during first two days.
- Fever drops and patient feels better by days 2-4.



The prodrome, or pre-eruptive stage, of the illness begins abruptly with fever, malaise, headache, muscle pain, prostration, and often nausea, vomiting, and backache.

The temperature usually rises to at least 38.5C (101F), and is often higher. The person usually appears quite ill. A severe febrile prodrome prior to rash onset is characteristic of smallpox, and helps differentiate it from many other causes of rash illness.

More than 90% of cases in both vaccinated and unvaccinated persons are of the ordinary type, which corresponds to the classical description of smallpox. By the third or fourth day of illness, the temperature usually falls and the patient feels somewhat better. At this point, the first visible lesions appear and the person becomes infectious.

Pre-Eruptive Symptoms 6942 CASES OF VARIOLA MAJOR

SYMPTOM	PERCENT
Fever	100
Headache	90
Chills	60
Backache	90
Pharyngitis	15
Vomiting	50
Diarrhea	10
Delirium	15
Abdominal Pain	13
Convulsions	7



Rao, Smallpox in Bombay, Kothari, Bombay, 1972



This table shows the initial symptoms described before the rash appeared in cases occurring in an outbreak in India in 1972.

Note that fever, headache, and backache are the most frequent non-rash symptoms associated with smallpox infection.

Progression of Smallpox Macules

- Minute red spots (first of tongue and palate).
- Lesions of the face and forehead (“herald spots”).
- Proximal part of extremities.
- Distal parts extremities.
- All in 1-2 days.
- May be difficult to see on dark skinned people.

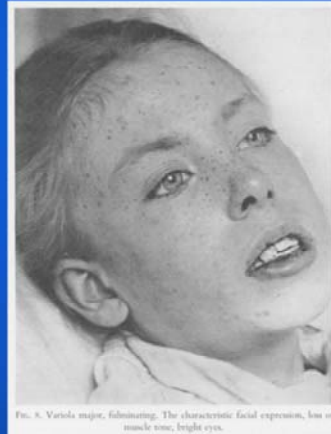

FIG. 8. Variola major, fulminating. The characteristic facial expression, loss of muscle tone, bright eyes.



The first visible lesions appear in the mouth as minute red spots on the tongue and oral and pharyngeal mucosa, about 24 hours before the appearance of rash on the skin.

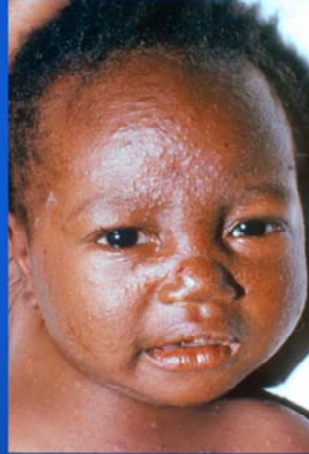Lesions in the mouth and pharynx enlarge and ulcerate quickly, releasing large amounts of virus into the saliva.

The skin rash usually appears first as a few macules, known as “herald spots” on the face, particularly the forehead. Lesions then appear on the proximal portions of the extremities, then spread to the trunk and distal portions of the limbs. Usually, the rash appears on all parts of the body within 24 hours.

Progression of Smallpox Papules

Day 2 of rash:

- Pharyngeal lesions evolve quickly to papules, vesicles, and break down (virus present).
- Raised above the skin.
- Fluid accumulating.

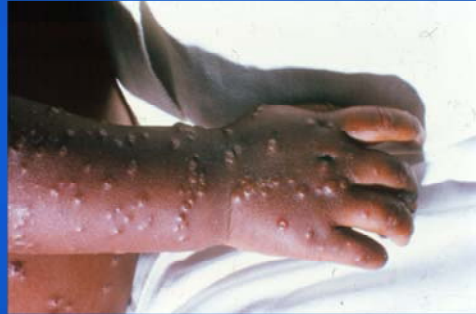

By the second day of the rash, the macules become raised papules.

Progression of Smallpox Vesicles

Day 3 and 4 of rash:

- Accumulation of fluid.
- Over next 24-48 hours, clear fluid becomes cloudy and begins to thicken.



By the third or fourth day, the lesions become vesicular, containing first an opalescent fluid, which then becomes opaque and turbid within 24 to 48 hours. The skin lesions of smallpox are typically surrounded by a faint erythematous halo. Fever usually rises again at about this time and remains high throughout the vesicular and pustular stages until scabs have formed over all the lesions.

Progression of Smallpox Vesicles

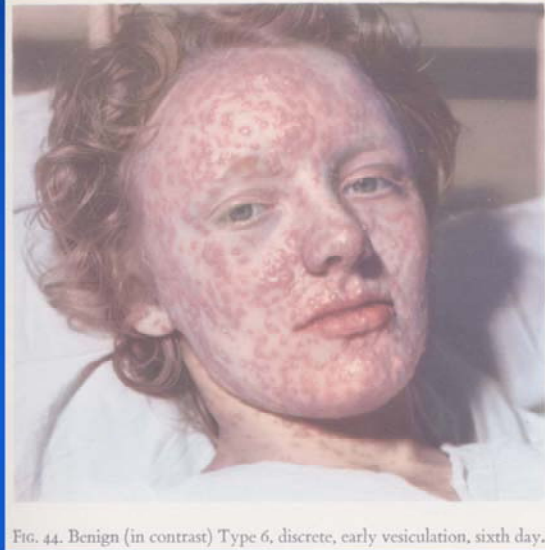


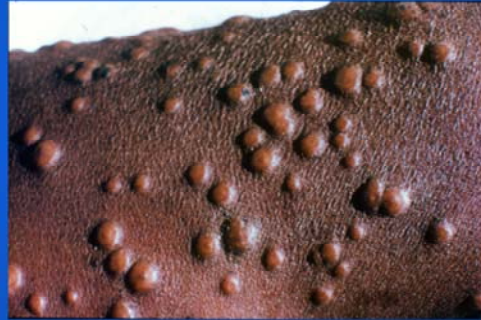FIG. 44. Benign (in contrast) Type 6, discrete, early vesiculation, sixth day.



The distended vesicles often have a central depression of varying size, making them dimpled or umbilicated. An umbilicated appearance often persists into the pustular stage, but as the lesion progresses they usually become flattened because of reabsorption of fluid. An umbilicated appearance is unusual in other rash illnesses, especially in varicella.

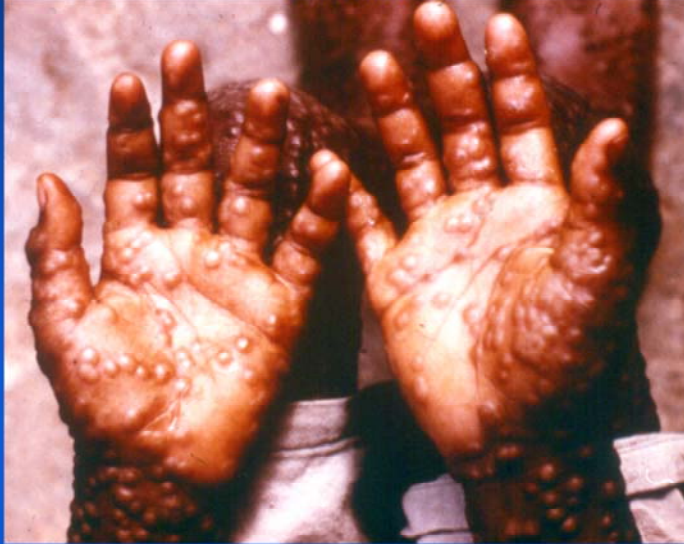Progression of Smallpox Pustules

- Vesicles become full of pus.
- Most lesions pustular by day 7.
- Reach their maximum size by day 11.
- As fluid absorbed, lesions become flatter.
- Feel like hard peas in skin.



By the sixth or seventh day, all the skin lesions have become pustules. The pustules are sharply raised, typically round, tense, and firm to the touch. The pustules are deeply embedded in the dermis, and are often described as “shotty,” similar to a small bead embedded in the skin.

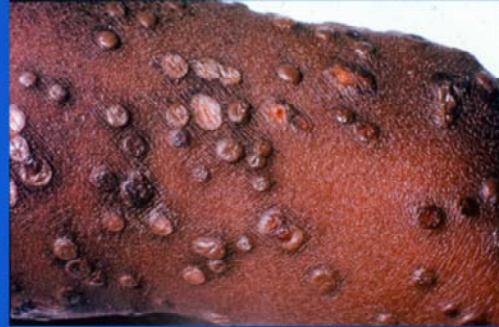Progression of Smallpox Pustules



Although lesions can become dense around the nose and mouth, the majority of lesions are discrete, separated by normal appearing skin. Lesions can appear on the palms and soles of the feet.

Scabs

- As fluid is absorbed scabs form.
- Scabs are infectious; thus patient is infectious until all scabs fall off.
- In areas of thick skin (palms and soles) lesions are embedded and may take 2-3 weeks to come off.



The pustules begin to form a crust at about day 10 of the rash. By about 14 days, most of the lesions have scabbed, and some have begun to separate. The scabs contain variola virus and are infectious, however the virus is bound in the fibrin matrix of the scab somewhat limiting the infectivity.

About three weeks after rash onset, scabs have separated, except on the palms and soles. Skin at the site of each lesion is depigmented and eventually become pitted scars.

Smallpox Eruption Over Time

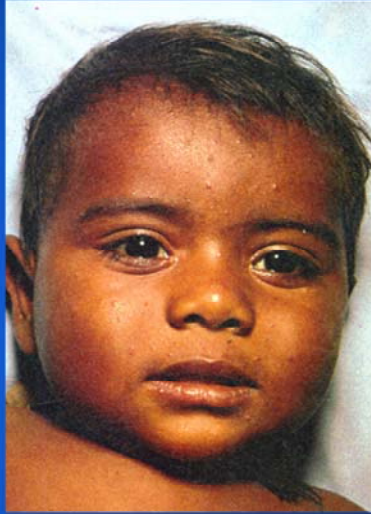- A major diagnostic characteristic of smallpox is that lesions in a given area are similar in appearance and feel.
- Progression occurs, however, from area to area:
 - Pharynx, Palate.
 - Face.
 - Proximal Extremities.
 - Hands and Feet.



So reviewing once more the rash...The major criteria to ascertain is that the lesions are similar in appearance, feel, and stage at any given time. There should not be “crops” of lesions in new stages of development, such as those that occur in varicella.

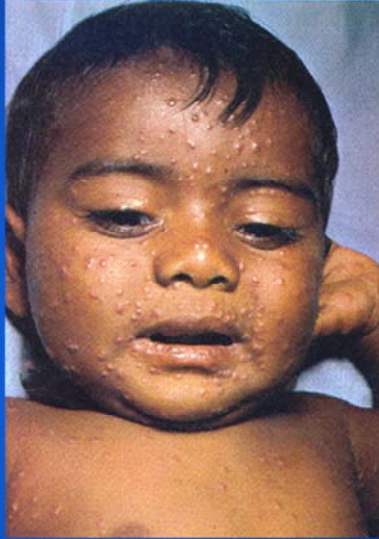Progression of the rash is fairly standard, beginning with the pharynx and palate, moving to the face and the proximal extremities.

Smallpox Day 2



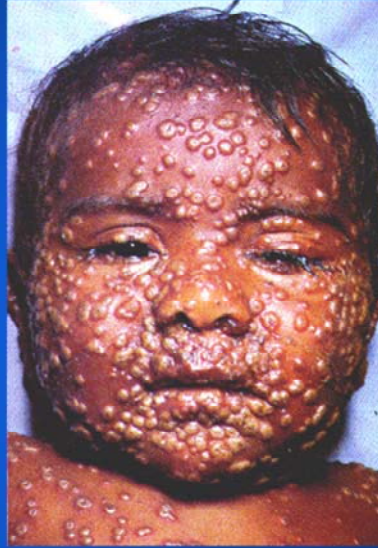Here we see the early papular stage.

Smallpox Day 4



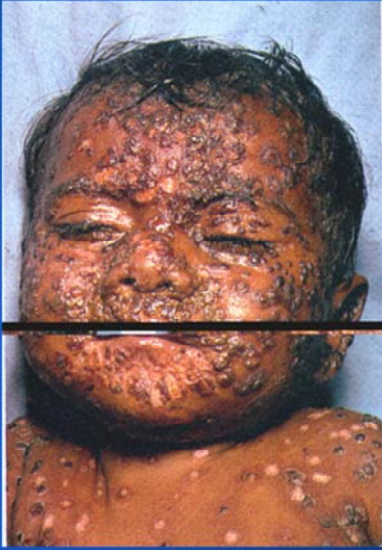Here we see the vesicular stage.

Smallpox Day 8



Here we see the pustular stage.

Smallpox Day 13



Scabbing and early scarring.

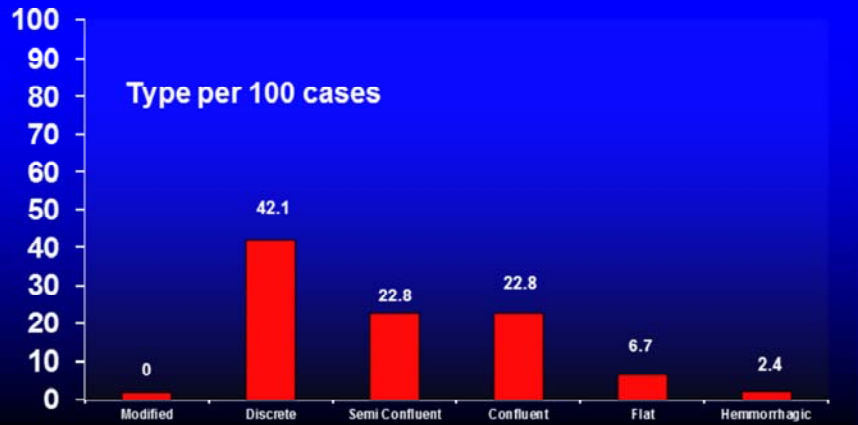
Types of Smallpox Rash

- No rash – Variola sine eruptione.
- Modified.
- Ordinary:
 - Discrete.
 - Semi-confluent.
 - Confluent.
- Flat.
- Hemorrhagic:
 - Early.
 - Late.



There are several types of smallpox rash that may be observed. There are 2 classification systems you may read about. We will focus on the WHO classification, which is based on the work of Dr. Rao, 1972. Ordinary smallpox accounts for most cases of variola major.

Smallpox Morbidity by Case Type Unvaccinated



*Rao, Smallpox in Bombay, Kothari, Bombay, 1972 (6942 cases)



Ordinary smallpox includes the 3 bars of discrete, semi-confluent, and confluent, accounting for about 88% of cases.

Smallpox Disease: Variola Major

“The severity of the disease depends on the reaction of the host to the virus...”

Dixon CW. Smallpox. Churchill, 1962.



There are four clinical presentations of variola major, based on the nature and evolution of the lesions. The relative vigor of the immune response probably determines the clinical presentation. The most frequent presentation is ordinary smallpox of variola major.

Types of Smallpox Rash Variola Sine Eruptione

- Fever 39 C.
- Headache, backache.
- Recovered in 48 hours.
- Requires laboratory studies.
- Virus isolation up to day 3.
- Neutralizing Antibody.



It is possible to be infected with smallpox, but not erupt in the rash. Patients experience the symptoms common to the prodrome, but it is usually of short duration. In order to diagnose this infection, laboratory workup is required.

Types of Smallpox Rash Modified

- Prodrome less severe.
- Usually no fever during rash.
- Lesions more superficial.
- Mostly in previously vaccinated people.



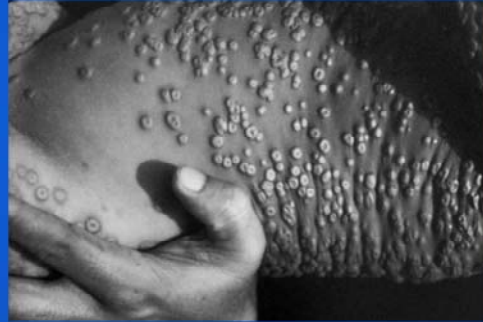Modified refers to the character of the eruption and the rapidity of its development. Modified smallpox occurs mostly in previously vaccinated people.

The prodromal illness still occurs but may be less severe than in the ordinary type. There is usually no fever during evolution of the rash. The skin lesions tend to evolve more quickly, are more superficial, and may not show the uniform characteristic of more typical smallpox.

The lesions are often few in number, but could be numerous, or even confluent. Regardless of the number of lesions, they usually evolve rapidly. Modified smallpox is rarely, if ever, fatal.

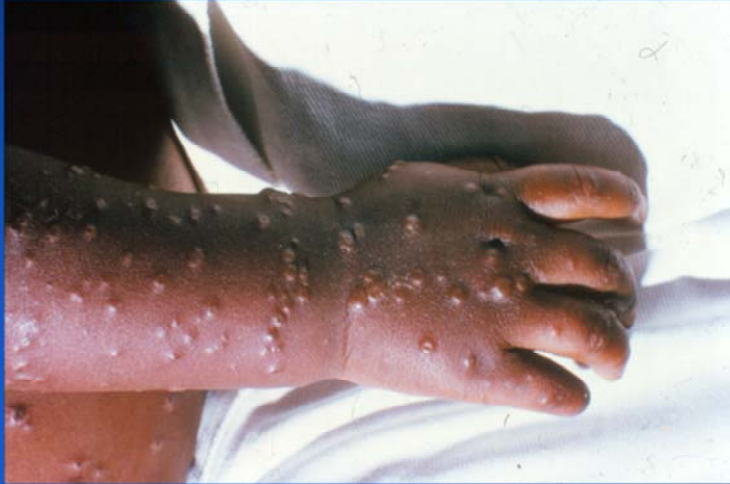Types of Smallpox Rash Ordinary - Discrete

Areas of normal skin
between pustules,
even on face.



Discrete refers to the type of rash in which areas of normal skin appear between the pustules, even on the face where the pustules tend to be very close together. This rash follows the typical progression we spoke of earlier.

Types of Smallpox Rash Ordinary - Discrete



This is another view of the discrete rash.

Disease Progression: Ordinary - Discrete Smallpox

- Sudden severe fever.
- Fever ↓ within 3 days, at rash onset.
- Discrete vesicles.
- Secondary fever with pustulation.
- Hoarseness and difficulty swallowing are rare.
- Hemorrhage in areas of trauma, or subconjunctival (vitamin C deficiency?).
- Tertiary fever = secondary infection.
- Patients often require minimal medical care.
- Complications rare. No systemic symptoms after first few days.

Most
common
type



Dixon CW. Smallpox. Churchill, 1962

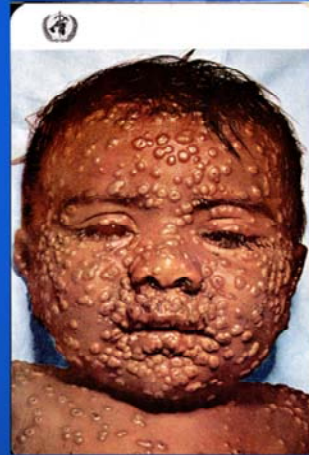

The disease progression of discrete smallpox is:

- Sudden severe fever
- Fever ↓ within 3 days, at rash onset
- Discrete vesicles
- Secondary fever with pustulation
- Hoarseness and difficulty swallowing are rare
- Hemorrhage in areas of trauma, or subconjunctival (vitamin C deficiency?)
- Tertiary fever = secondary infection
- Patients often require minimal medical care
- Complications rare. No systemic symptoms after first few days

Types of Smallpox Rash Ordinary - Semi-Confluent

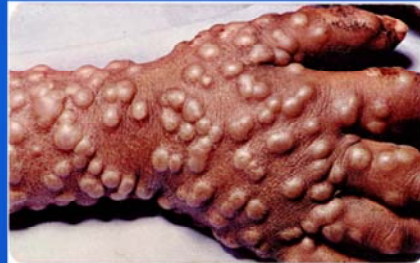Pustules confluent on face but discrete elsewhere.



When the patient has a semi-confluent rash, the pustules are extremely close together on the face, but are discrete elsewhere on the body.

Types of Smallpox Rash Ordinary - Confluent

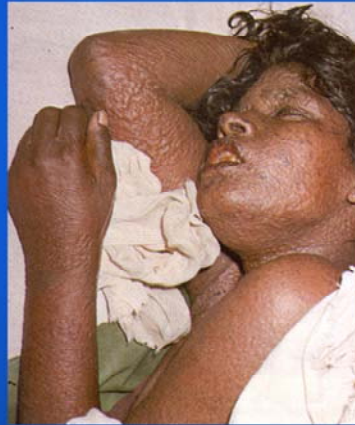Confluent rash on
face and forearms.



The confluent rash description is used when the pustules are very close together on the face and forearms with little normal skin appearing between them.

Types of Smallpox Rash Flat

Pustules confluent or semiconfluent – appear flat.



Two types of variola major were particularly severe with a high fatality rate. These were flat, or malignant smallpox, and hemorrhagic smallpox.

Flat-type smallpox was so called because the lesions remained more or less flush with the skin at the time when raised vesicles formed in ordinary smallpox. In a large series of smallpox cases from India, flat type smallpox accounted for 5% - 10% of cases.

It's not known with certainty why some people develop this type of disease, but many cases occurred in children. The prodrome and constitutional symptoms are severe and last 3 or 4 days. The fever remains elevated throughout the course of the illness and the patient has severe toxic symptoms. The rash on the tongue and palate is usually extensive, and the skin lesions develop very slowly.

WHO Flat Smallpox (Dixon Type 2 - Malignant Confluent)

Rare

- Clinical course like that of burn or Stevens-Johnson Syndrome patients.
- Sudden onset, T = 38.3-38.9.
- Malaise, headache, general muscle aches, backache (often severe), chest pain.
- Abdominal pain, vomiting:
 - Mucosal/submucosal hemorrhage.
 - May have melena.
 - Acute abdomen may lead to laparotomy.
- Anxiety... "peculiar mental alertness."



Dixon CW. Smallpox. Churchill, 1962



The symptoms associated with the flat, Dixon Type 2 – Malignant Confluent smallpox include:

- Clinical course like that of burn or Stevens-Johnson Syndrome patients.
- Sudden onset, T = 38.3-38.9.
- Malaise, headache, general muscle aches, backache (often severe), chest pain.
- Abdominal pain, vomiting:
 - Mucosal/submucosal hemorrhage.
 - May have melena.
 - Acute abdomen may lead to laparotomy.
- Anxiety... "peculiar mental alertness."

Flat Smallpox Days 2 and 3

- Tachycardia.
- Irregular petechial and macular rash of chest, neck, back, upper arms.
- Dusky erythema of face:
 - Marked intracuticular edema.
 - Scalded appearance of skin, like a severe sunburn.
- Vesicles 4-5 mm, superficial, flattened.



Dixon CW. Smallpox. Churchill, 1962



Symptoms associated with days 2 and 3 of flat smallpox include:

- Tachycardia.
- Irregular petechial and macular rash of chest, neck, back, upper arms.
- Dusky erythema of face:
 - Marked intracuticular edema.
 - Scalded appearance of skin, like a severe sunburn.
- Vesicles 4-5 mm, superficial, flattened.

Flat Smallpox Day 8-14

- Day 8-11: Skin vesicles soft, flat, velvety, some with huge confluent bullae (like Stevens Johnson Syndrome).
- Day 12-13: Massive exfoliation, like a severe burn.
- Keratitis → blindness.
- Hemoptysis, uterine hemorrhage.
- Absence of platelets.
- Neutropenia, lymphocytosis.



Dixon CW. Smallpox. Churchill, 1962



Symptoms associated with days 8 through 14 of flat smallpox include:

- Day 8-11: Skin vesicles soft, flat, velvety, some with huge confluent bullae (like Stevens Johnson Syndrome)
- Day 12-13: Massive exfoliation, like a severe burn
- Keratitis → blindness
- Hemoptysis, uterine hemorrhage
- Absence of platelets
- Neutropenia, lymphocytosis

Flat Smallpox Third Week

- Cannot eat or drink, from severe throat pain with swallowing.
- Huge areas of skin peeling off with even slight pressure:
 - “Widespread stripping of epithelium.”
 - “Mortification” from tissue destruction.
 - Fetid odor.
- Bacterial sepsis.
- Death (70%) from severe tissue destruction.

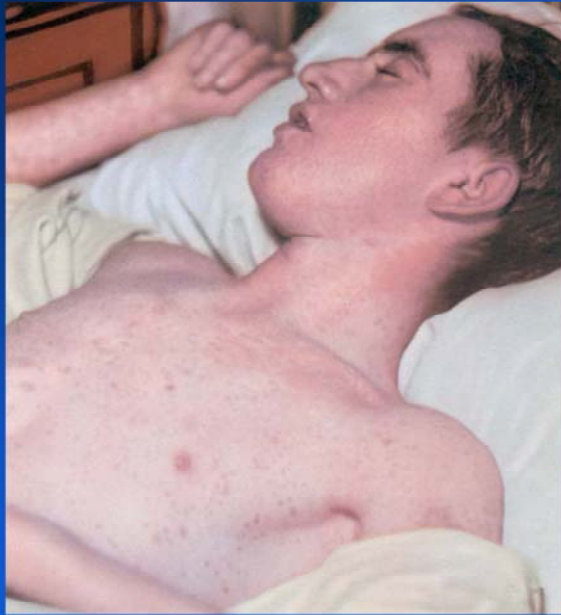

Dixon CW. Smallpox. Churchill, 1962



Symptoms associated with the third week of flat smallpox include:

- Cannot eat or drink, from severe throat pain with swallowing
- Huge areas of skin peeling off with even slight pressure
 - “Widespread stripping of epithelium”
 - “Mortification” from tissue destruction
 - Fetid odor
- Bacterial sepsis
- Death (70%) from severe tissue destruction



Flat Smallpox


- Sunburn.
- Facial Rash with Fine Flat Vesicles.
- Predominates on face, little on chest.



Dixon CW. Smallpox. Churchill, 1962, fig 17





Flat type disease in a light skinned person may be more difficult to diagnose visually.



Flat Smallpox

Intense Skin Edema with Loss of Normal Body and Skin Contours.

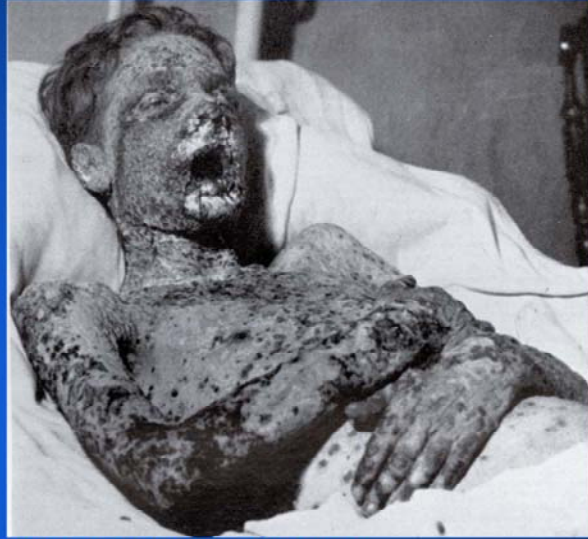Fenner, Henderson et al. Smallpox and its eradication. 1988. WHO. Page 33.



By the seventh or eighth day, the lesions are flat and appear to be buried in the skin. Unlike ordinary type smallpox, the vesicles contain very little fluid and do not appear umbilicated. The lesions are soft and velvety to the touch. Lesions may contain hemorrhages.

Patients with flat type smallpox often appear toxic and have crusting around the mouth from oral lesions. The prognosis for this form of smallpox is grave and most cases are fatal. Flat type smallpox can be difficult to diagnose because the typical skin lesions do not develop.

Flat Smallpox “Mortification”



Dixon CW. Smallpox. Churchill, 1962, fig 40



Here we see the severe skin disruption and distortion of normal landmarks.

Flat Smallpox Treatment Considerations

- Tissue edema:
 - Expand intravascular volume with isotonic crystalloid.
 - Replace protein loss as indicated with albumin.
 - Monitor electrolytes and renal function.
 - Central venous access to monitor central venous pressure and oxygen delivery, and guide treatment.



The next several slides discuss treatment considerations for flat smallpox. These treatments include:

- Tissue edema:
 - Expand intravascular volume with isotonic crystalloid.
 - Replace protein loss as indicated with albumin.
 - Monitor electrolytes and renal function.
 - Central venous access to monitor central venous pressure and oxygen delivery, and guide treatment.

Emphasis is on appropriate fluid resuscitation.

Flat Smallpox Treatment Considerations

- Mouth and GI lesions:
 - Enteral alimentation if possible, via nasogastric or nasojejunal tube.
 - Intravenous hyperalimentation if needed.
- Tracheal lesions may require intubation for airway obstruction.
- GI Bleeding, Disseminated Intravascular Coagulation (DIC):
 - Platelets, Fresh Frozen Plasma.
 - Antacids.



- Mouth and GI lesions:
 - Enteral alimentation if possible, via nasogastric or nasojejunal tube.
 - Intravenous hyperalimentation if needed.
- Tracheal lesions may require intubation for airway obstruction.
- GI Bleeding, Disseminated Intravascular Coagulation (DIC):
 - Platelets, Fresh Frozen Plasma.
 - Antacids.

Patients may require treatment for bleeding – blood product replacement.

Flat Smallpox Treatment Considerations

- “Burn” wounds:
 - Fluids as noted:
 - “Sunburn” with vesicles \Rightarrow first and second degree burns.
 - “Mortification” \Rightarrow third degree burns.
 - Volume expansion may limit depth and extent of tissue destruction.
 - Debridement of devitalized tissue to prevent infection.
 - Topical antibacterial treatment.



- “Burn” wounds:
 - Fluids as noted:
 - “Sunburn” with vesicles \Rightarrow first and second degree burns.
 - “Mortification” \Rightarrow third degree burns.
 - Volume expansion may limit depth and extent of tissue destruction.
 - Debridement of devitalized tissue to prevent infection.
 - Topical antibacterial treatment.

Flat Smallpox Treatment Considerations

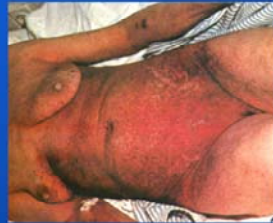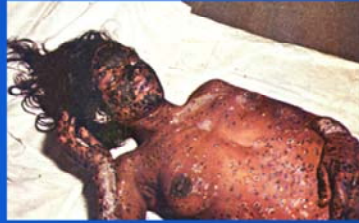- Secondary infection:
 - Blood cultures, lesion cultures.
 - Treat as needed:
 - Staphylococcus.
 - Group A streptococcus.
 - Pseudomonas aeruginosa possible, as in a burn wound.



- Secondary infection:
 - Blood cultures, lesion cultures.
 - Treat as needed:
 - Staphylococcus.
 - Group A streptococcus.
 - Pseudomonas aeruginosa possible, as in a burn wound.

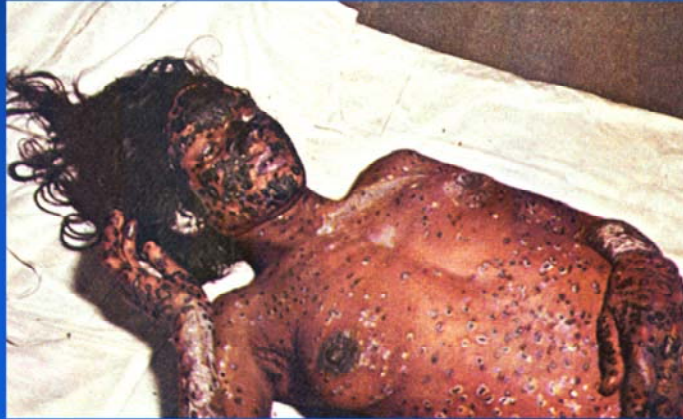Hemorrhagic Smallpox

- Widespread hemorrhage into skin.
- Two types (early and late) both 98% case fatality.



Hemorrhagic smallpox is a severe and uncommon form of smallpox that is almost always fatal. It involves extensive bleeding into the skin, mucous membranes and gastrointestinal tract. In the large Indian series, hemorrhagic disease occurred in about 2% of cases, and occurred mostly in adults. The prodrome, which can be prolonged, is characterized by fever, intense headache and backache, restlessness, a dusky flush or sometimes pallor of the face, extreme prostration and toxicity. There is little or no remission of fever throughout the illness. Hemorrhagic manifestations can occur early or late in the course of the illness.

Hemorrhagic Smallpox

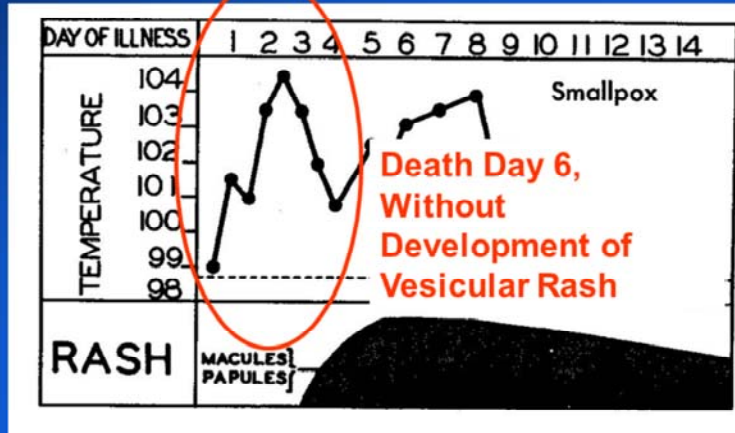


Hemorrhagic manifestations appear on the second or third day as subconjunctival bleeding, bleeding from the mouth or gums, and other mucous membranes, petechia in the skin, epistaxis, and hematuria.

Death often occurs suddenly between the fifth and seventh days of illness, when only a few insignificant maculopapular cutaneous lesions are present.

This woman has late hemorrhagic manifestations. In patients who survive for 8 to 10 days the hemorrhages appear in the early eruptive period. The rash is flat and does not progress beyond the vesicular stage. Hemorrhagic smallpox could be easily misdiagnosed as meningococcal bacteremia because of the hemorrhages and lack of typical smallpox vesicles and pustules.

Early Hemorrhagic Smallpox Toxemia of the Prodrome continues until Death



"Variolous toxemia is precisely analagous to that of scarlet fever"

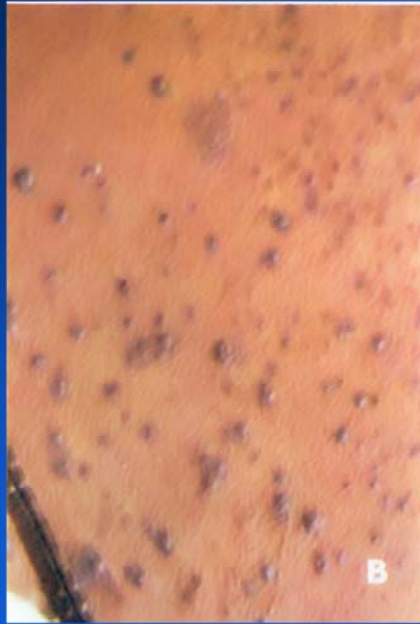


Ricketts, Diagnosis of Smallpox. 1908. Krugman, 1976 (graph)



These patients present severely ill and may die before developing a vesicular rash.

Hemorrhagic Smallpox



- Petechia.
- Purpuric Papules.
- Does Not Look Like Smallpox.



Fenner, Henderson et al. Smallpox and its eradication. 1988.
WHO. Plate 1.23B



When they do develop the rash it may not look at all like smallpox.

Hemorrhagic Smallpox

- Hyper-acute course.
- Inflammatory Shock.
- Shock, like meningococemia.
- “Intense prostration” with severe headache and backache. Alert, apprehensive.
- Blotchy, blanching erythema arms, trunk.
- Petechiae and hemorrhage mouth and skin.
- May develop superficial vesicles.
- Few hemorrhages in respiratory + GI mucosa, myocardium.
- Acute Respiratory Distress Syndrome possible.
- Blood counts may suggest leukemia, include myeloblasts.

Rare



Dixon CW. Smallpox. Churchill, 1962



These patients will have a quickly progressive disease course and often develop signs and symptoms of inflammatory shock.

- Hyper-acute course.
- Inflammatory Shock.
- Shock, like meningococemia.
- “Intense prostration” with severe headache and backache. Alert, apprehensive.
- Blotchy, blanching erythema arms, trunk.
- Petechiae and hemorrhage mouth and skin.
- May develop superficial vesicles.
- Few hemorrhages in respiratory + GI mucosa, myocardium.
- Acute Respiratory Distress Syndrome possible.
- Blood counts may suggest leukemia, include myeloblasts.

Hemorrhagic Smallpox Treatment Considerations

- Treat as for inflammatory shock:
 - Isotonic fluid resuscitation.
 - Pressors when needed.
 - Tracheal intubation / mechanical ventilation as required for support,
 - or for airway obstruction from laryngeal hemorrhage.
 - Warm room to prevent vasoconstriction and distal tissue necrosis.



The next several slides discuss treatment considerations for hemorrhagic smallpox. These treatments include:

- Treat as for **inflammatory shock**:
 - Isotonic fluid resuscitation.
 - Pressors when needed.
 - Tracheal intubation / mechanical ventilation as required for support,
 - or for airway obstruction from laryngeal hemorrhage.
 - Warm room to prevent vasoconstriction and distal tissue necrosis.

Hemorrhagic Smallpox Treatment Considerations

- Fever and possible secondary bacteremia:
 - Clindamycin (as for Strep/staph TSS),
 - Cefotaxime (as for meningococemia),
 - and/or penicillin or ampicillin/sulbactam pending bacterial cultures of blood.
- Bleeding: DIC and GI mucosal lesions:
 - Measure PT, PTT, Platelets.
 - Fresh Frozen plasma as indicated.
 - Platelet infusions if needed.
 - Antacids.



- Fever and possible secondary bacteremia:
 - Clindamycin (as for Strep/staph TSS),
 - Cefotaxime (as for meningococemia),
 - and/or penicillin or ampicillin/sulbactam pending bacterial cultures of blood.
- Bleeding: DIC and GI mucosal lesions:
 - Measure PT, PTT, Platelets.
 - Fresh Frozen plasma as indicated.
 - Platelet infusions if needed.
 - Antacids.

Hemorrhagic Smallpox Treatment Considerations

- Intense tissue edema:
 - Isotonic crystalloid to expand intravascular volume.
 - Albumin if severe hypoproteinemia.
- Nutritional support: enteral or parenteral alimentation starting early in illness.
- Narcotics/anxiolytics for pain/anxiety.



- Intense tissue edema:
 - Isotonic crystalloid to expand intravascular volume.
 - Albumin if severe hypoproteinemia.
- Nutritional support: enteral or parenteral alimentation starting early in illness.
- Narcotics/anxiolytics for pain/anxiety.

Hemorrhagic Smallpox Other Possible Treatments

- Activated protein C improves survival in patients with severe sepsis.
 - Bernard GR, et al. Efficacy and safety of recombinant human activated protein C for severe sepsis. *NEJM* 2001;344:699-709
- Intravenous Immune globulin (2 grams/kg as a single dose) improves survival in streptococcal toxic shock.
 - McGeer KR, et al. Intravenous Immunoglobulin appears to be effective for streptococcal toxic shock syndrome. *Clin Infect Dis.* 1999;28:800-7.



Bleeding is a side effect → No!



These are some possible treatments that have not been used against smallpox before, but are currently used to treat critically ill patients with severe septic shock.

WHO Classification of Smallpox, and Case-Fatality Rates by Case Type

Type	Case Fatality Rate %
Hemorrhagic	100%
Flat	>90%
Ordinary-confluent	50-75%
Ordinary-semiconfluent	25-50%
Ordinary-discrete	<10%
Vaccine-modified	<10%



Koplan JP and Foster SO. Smallpox: Clinical Types, Causes of Death, and Treatment. JID 1979;140:440-1



In fatal cases, death usually occurs between the tenth and sixteenth days of the illness.

This table shows the fatality rates for smallpox. Hemorrhagic and flat types have the highest fatality rates, with ordinary smallpox carrying about a 30% overall mortality rate, historically. It is not yet known how advanced supportive care and the increased rates of immunocompromising medical conditions will influence the mortality rates in the 21st century.

Mortality Risk Factors

- Community vs. Hospital Diagnosis.
- Type of Virus (Major vs. Minor).
- Vaccination Status.
- Case Type.
- Age of Infection.
- Environmental sanitation (soap and water).
- Treatment (antibiotics).
- Antivirals ?



The cause of death from smallpox is not clear, but the infection is now known to involve multiple organs. Circulating immune complexes or an uncontrolled immune response may be contributing factors, as well as overwhelming viremia and soluble variola antigens.

A number of other factors may affect the outcome of disease and some of these are listed here.

In addition, whether or not the patient was diagnosed and managed in a hospital affected outcome. As previously discussed, patients with variola minor had a much lower mortality rate. Those who were previously vaccinated did much better, as did those who were younger. And good environmental sanitation helped to prevent secondary infections.

With the use of antibiotics and the possible use of antivirals in today's society, we might be able to improve outcomes, should we have to deal with this disease again.

Smallpox Sequelae: All Types

- Pock Marks:
 - Scarring.
 - Social effects.
 - Epidemiologic importance – scar survey for cases.
- Blindness (Hughes et al, Bangladesh):
 - Corneal Opacities 2.1%.
 - Blindness 0.9%.
- Limb Deformities.



For all types of smallpox, the outcome of the infection is either recovery – with or without sequelae – or death.

Those who survive are permanently scarred. Blindness from eye involvement is also common. Recovery results in long lasting immunity to reinfection with variola virus, and second cases of smallpox are rare, if they occur at all. There is no evidence of chronic or recurrent infection with variola virus.

Sequelae Scarring



This slide depict scarring sequelae.

Therapeutic Treatments for Smallpox

- Vaccinia Immune Globulin – NO!
- Antivirals:
 - None approved in the US for use in smallpox.
 - Administered intravenously.
 - Can cause serious renal toxicity.
 - Off-label use.



Vaccinia Immune Globulin is not effective against smallpox infection and should not be used.

No antiviral drug is currently approved for the treatment of smallpox. Recent studies suggest that the antiviral drug cidofovir might be useful as a therapeutic agent. But the drug must be administered intravenously, and can cause serious renal toxicity.

In addition, use of cidofovir for the treatment of smallpox would be an off label use. Antiviral therapy with cidofovir or other drugs subsequently found to have anti-variola activity might be considered, but would be used under an investigational new drug protocol by an infectious disease specialist.

Cidofovir

- Active against some DNA viruses.
- Nucleotide analogue, inhibits viral DNA polymerase.
- FDA approved only for treatment of CMV retinitis in persons with AIDS.
- Never before used to treat smallpox in humans



Lea AP, Bryson HM. Cidofovir. Drugs 1996;52:225-30



Cidofovir:

- Active against some DNA viruses.
- Nucleotide analogue, inhibits viral DNA polymerase.
- FDA approved only for treatment of CMV retinitis in persons with AIDS.

Cidofovir Dosing and Toxicity

- Usual Dose = 5 mg/kg, intravenously, once weekly, with probenecid and fluid therapy.
- Cleared in kidneys.
- Toxicities:
 - Nephrotoxicity, with proteinuria and ↑ creatinine.
 - Neutropenia.
- Carcinogenicity



Lea AP, Bryson HM. Cidofovir. Drugs 1996;52:225-30



The dosing and toxicity associated with Cidofovir are:

- Usual Dose = 5 mg/kg, intravenously, once weekly, with probenecid and fluid therapy.
- Cleared in kidneys.
- Toxicities:
 - Nephrotoxicity, with proteinuria and ↑ creatinine.
 - Neutropenia.

Summary Treatments for Smallpox

- All patients may require supportive care.
- Flat / Hemorrhagic: Treat as for shock.
- Semiconfluent/confluent: Treat as for a burn.
- All types: Bacterial superinfection likely.
- Always consider:
 - Dehydration, renal failure.
 - Malnutrition.
- Role of antiviral medications uncertain.



All patients may require supportive care, such as infection control, fluid therapy, and possible ventilatory assistance. (Remember airway, breathing, circulation).

Flat and hemorrhagic types of smallpox should be treated with the same therapies used to treat shock, such as fluid resuscitation.

Patients with semiconfluent and confluent types of may be expected to have therapeutic issues similar to patients who have extensive skin burns. These may include “wound” care, prevention of secondary infection, and, again, fluid resuscitation.